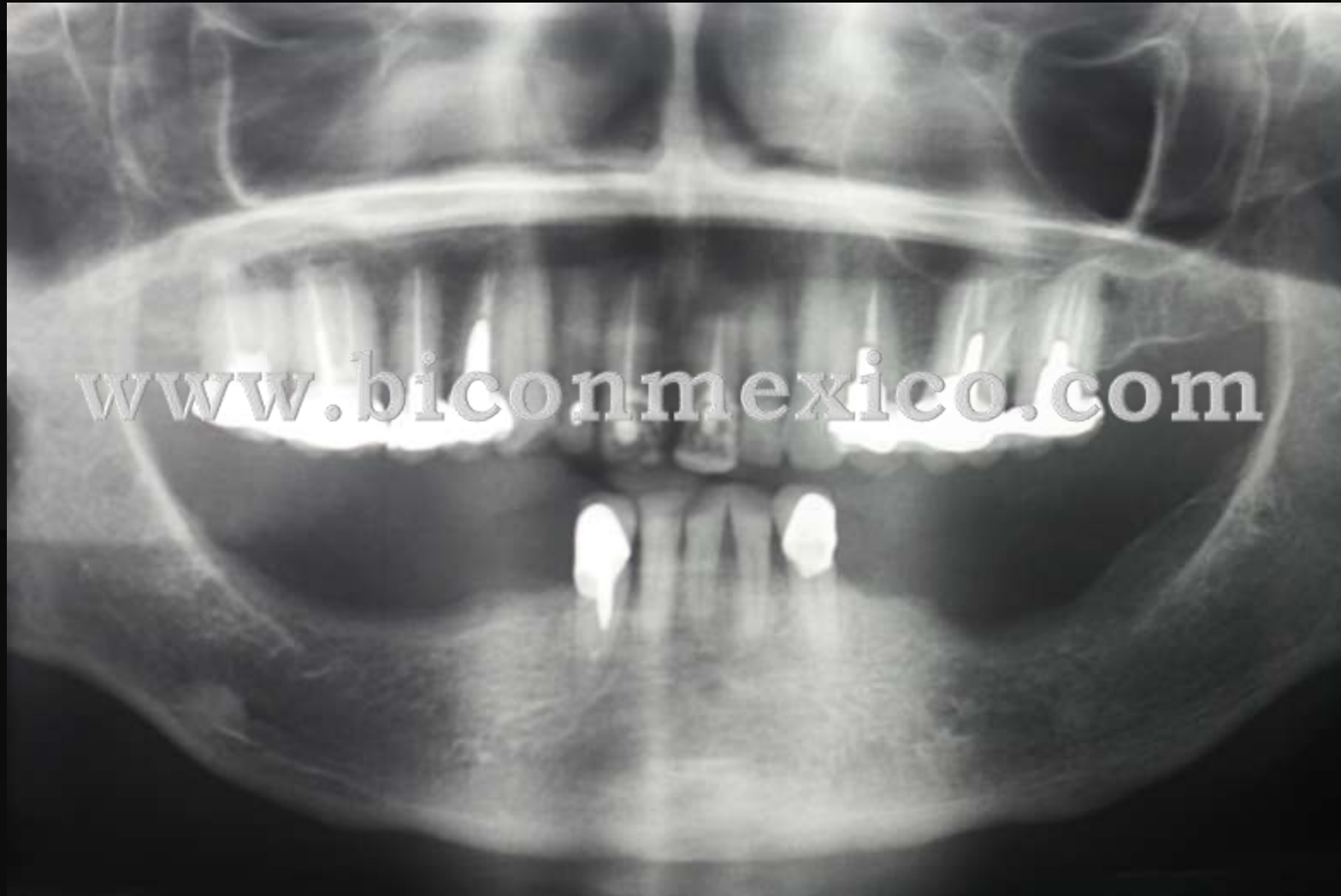
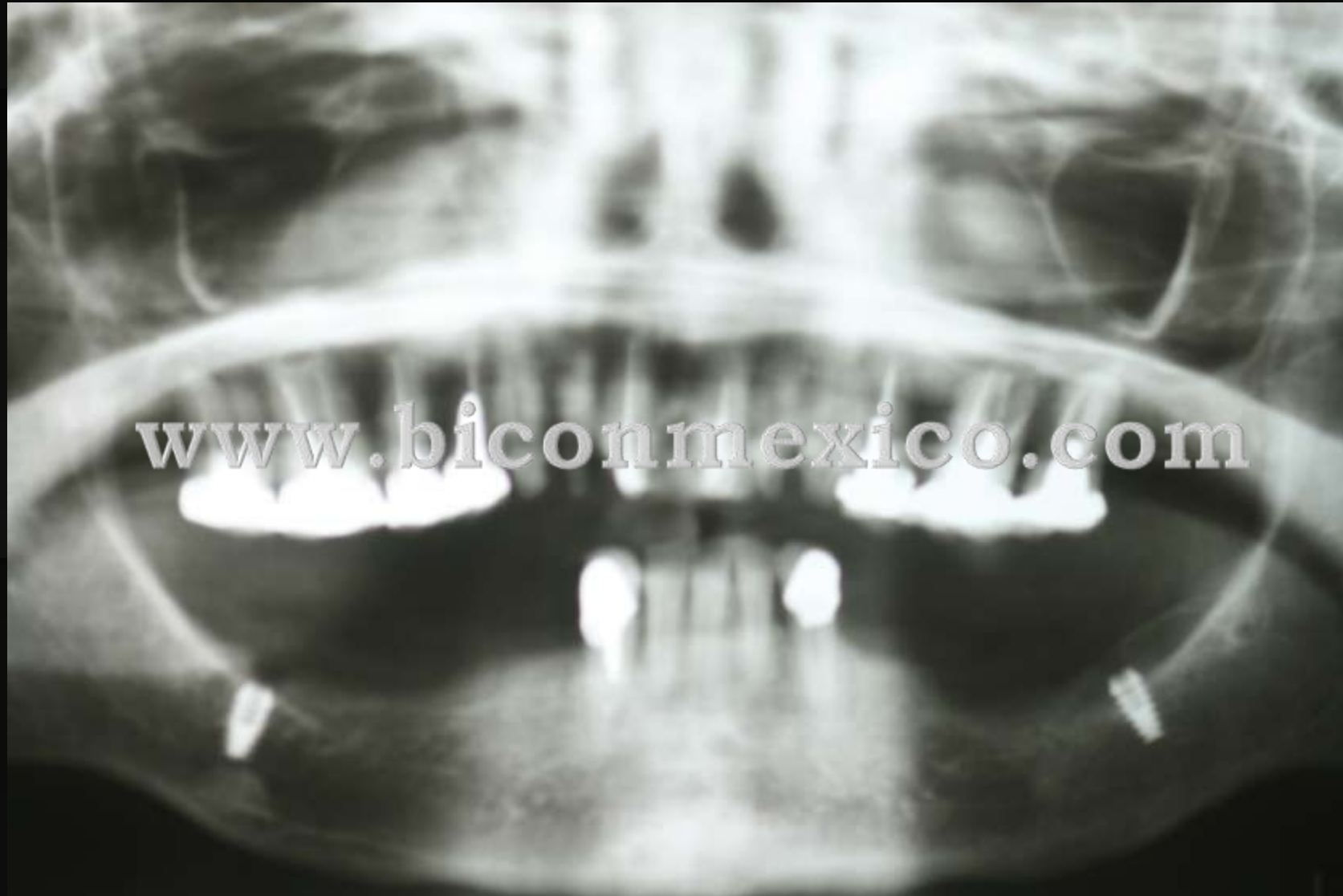
Caso clínico
Clase I de Kennedy

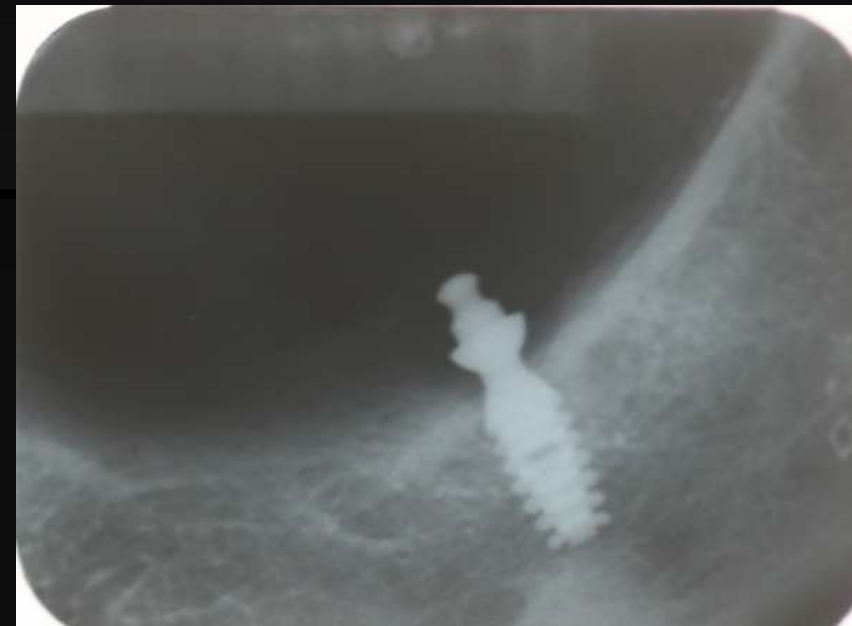
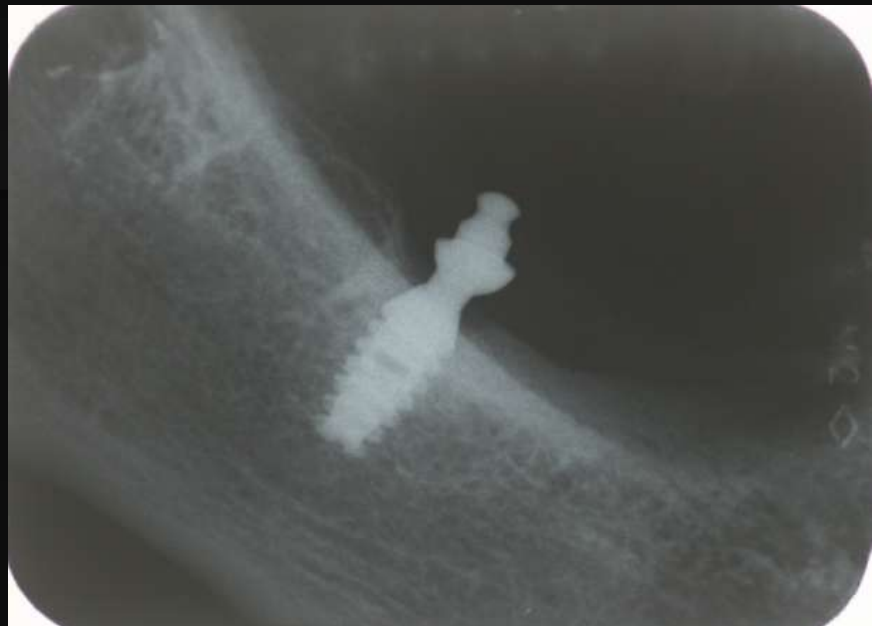
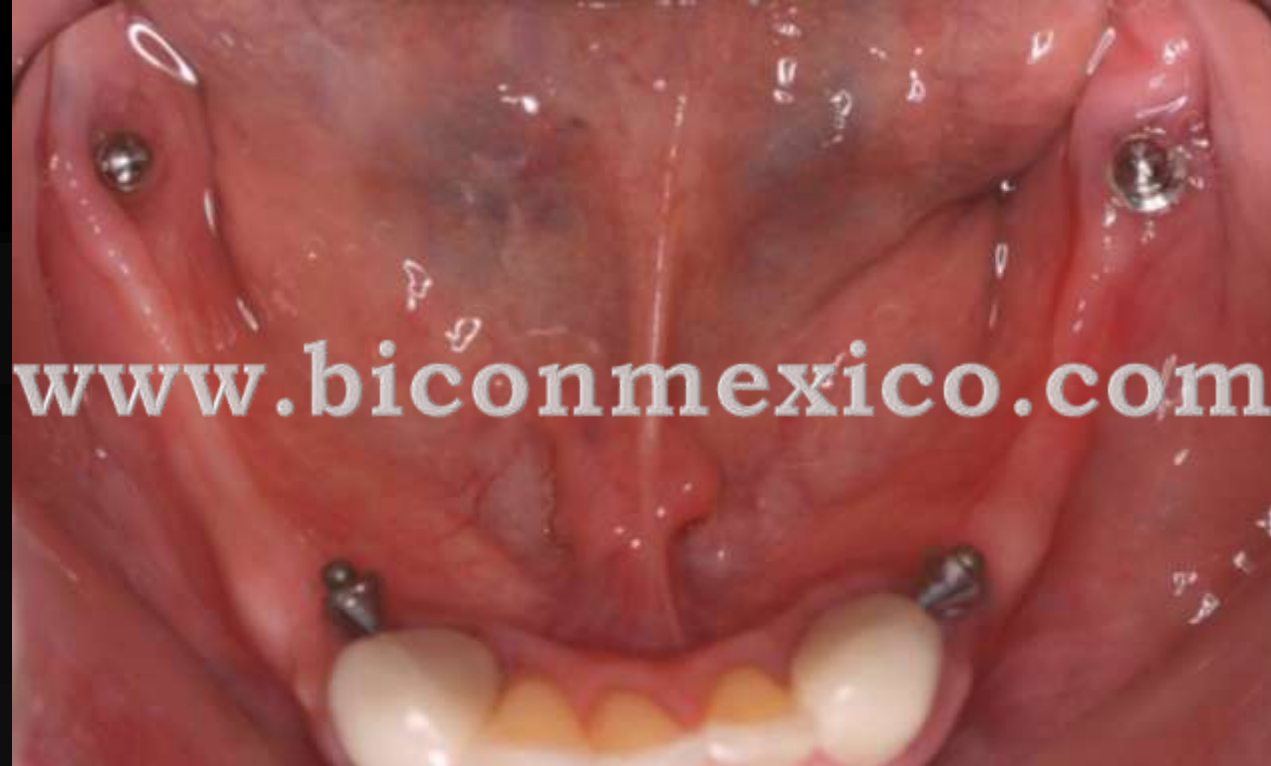
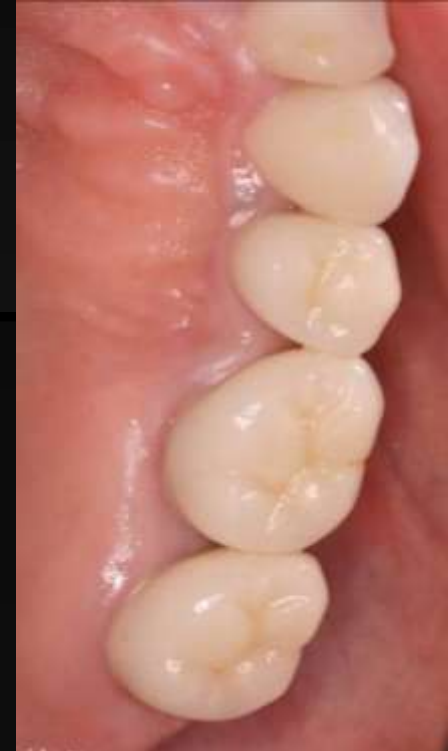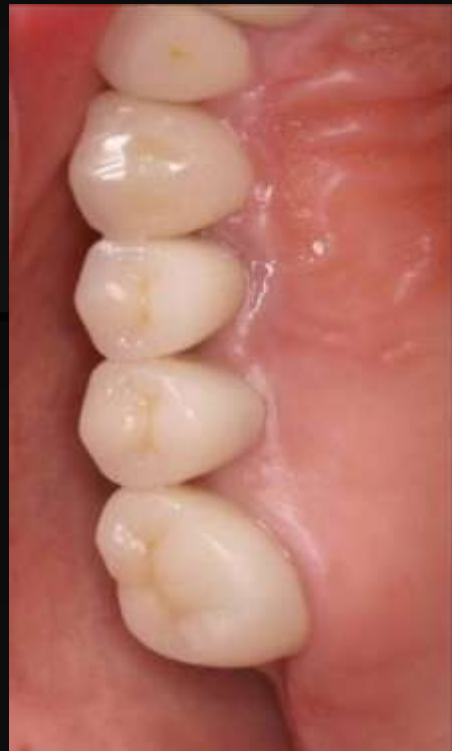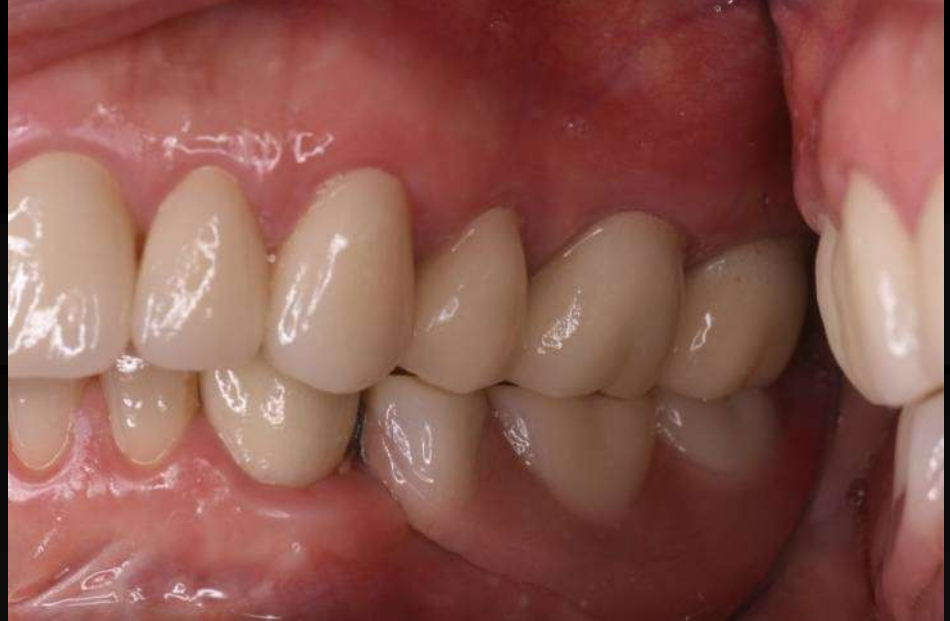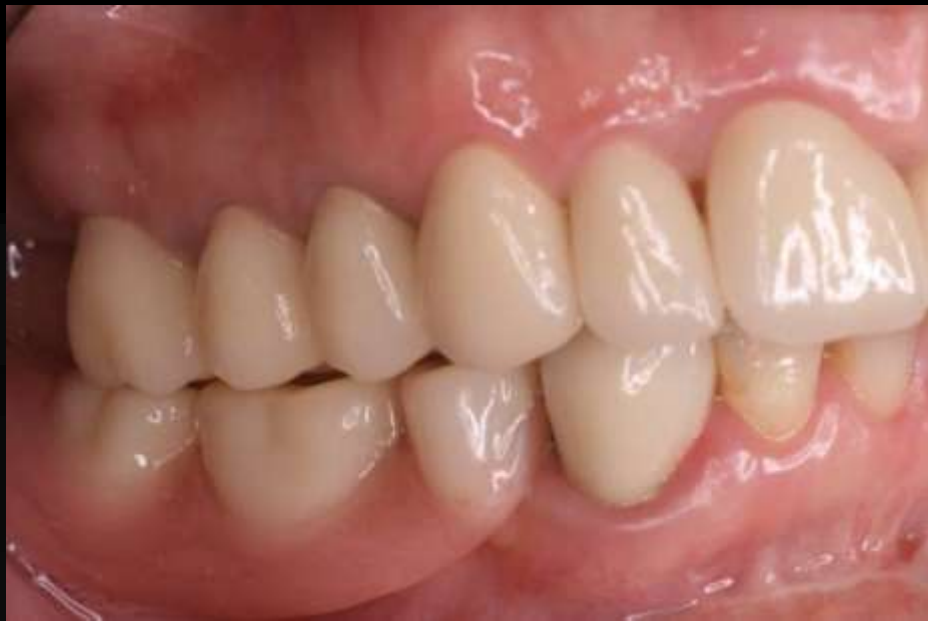Oct 2009



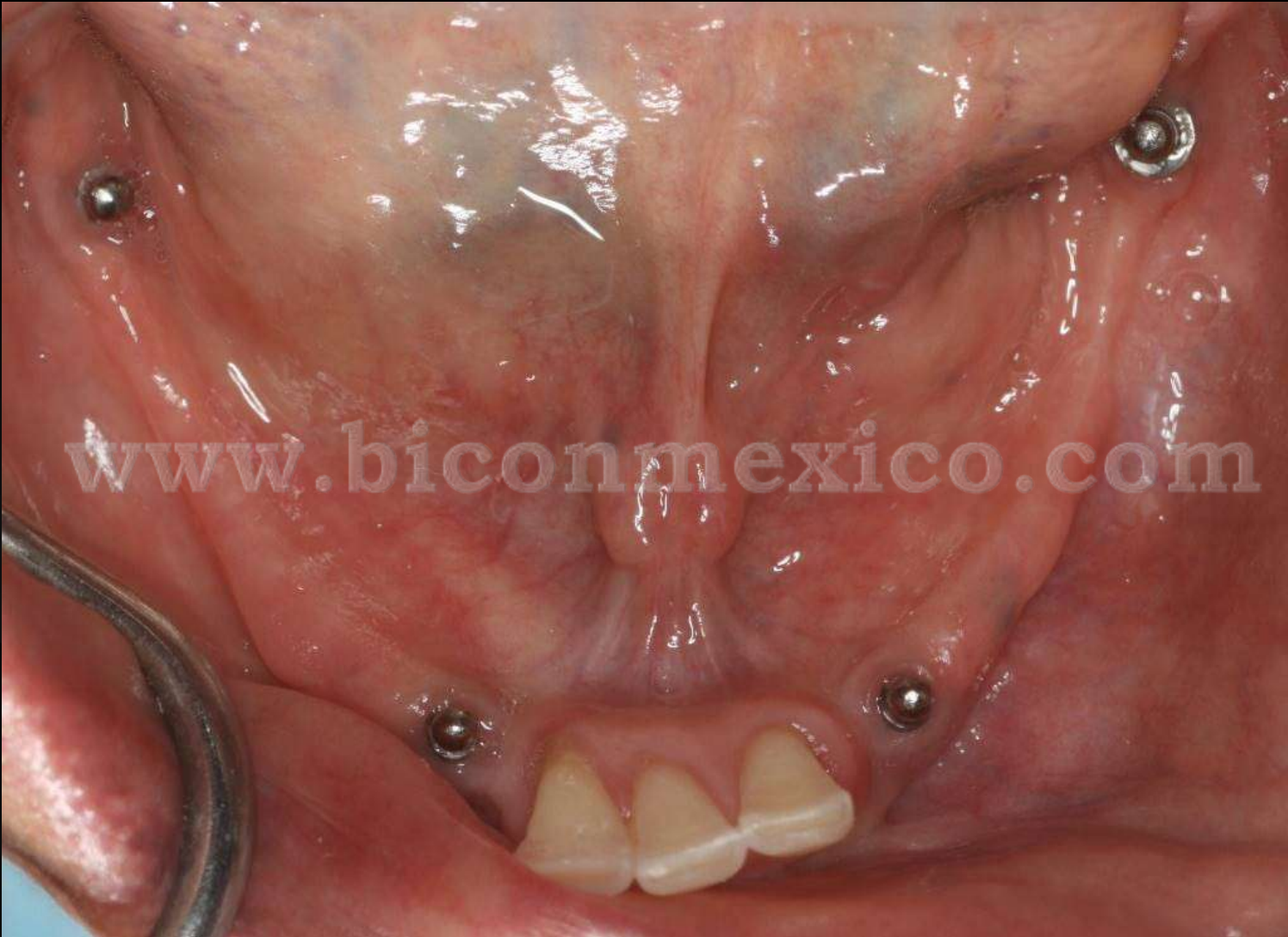www.biconmexico.com

**Mayo
2010**

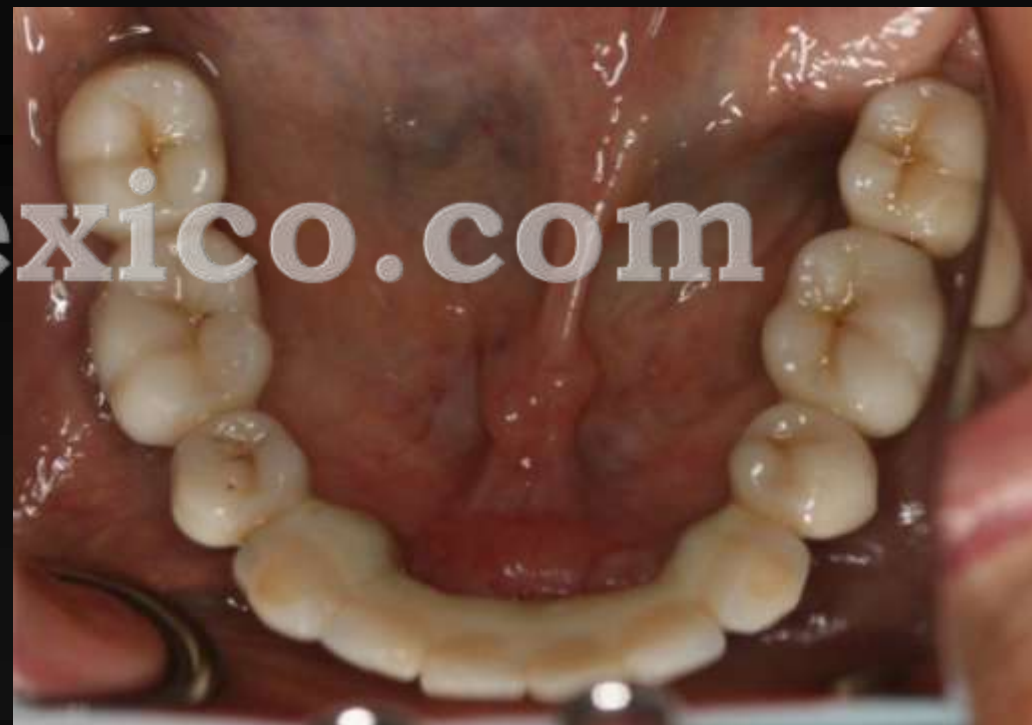
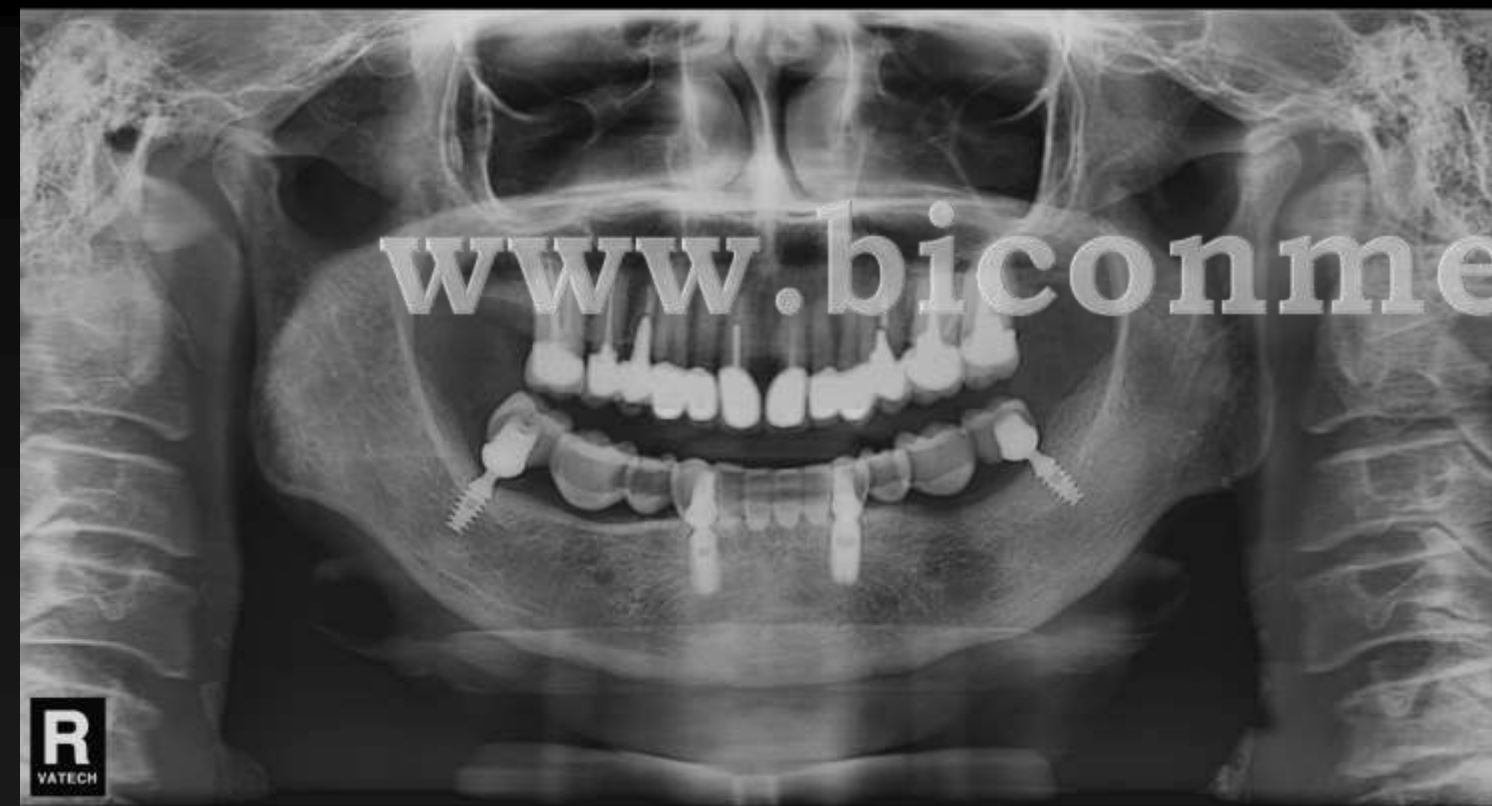


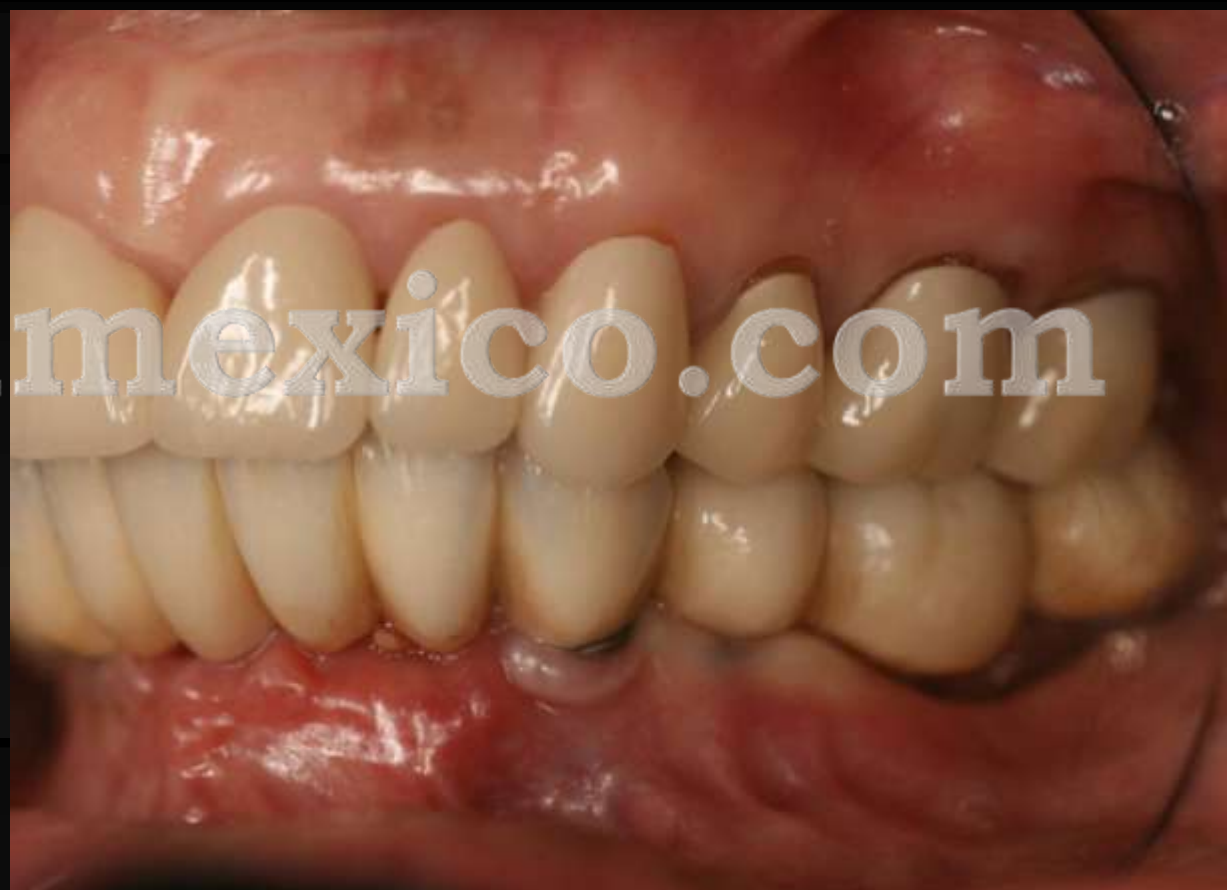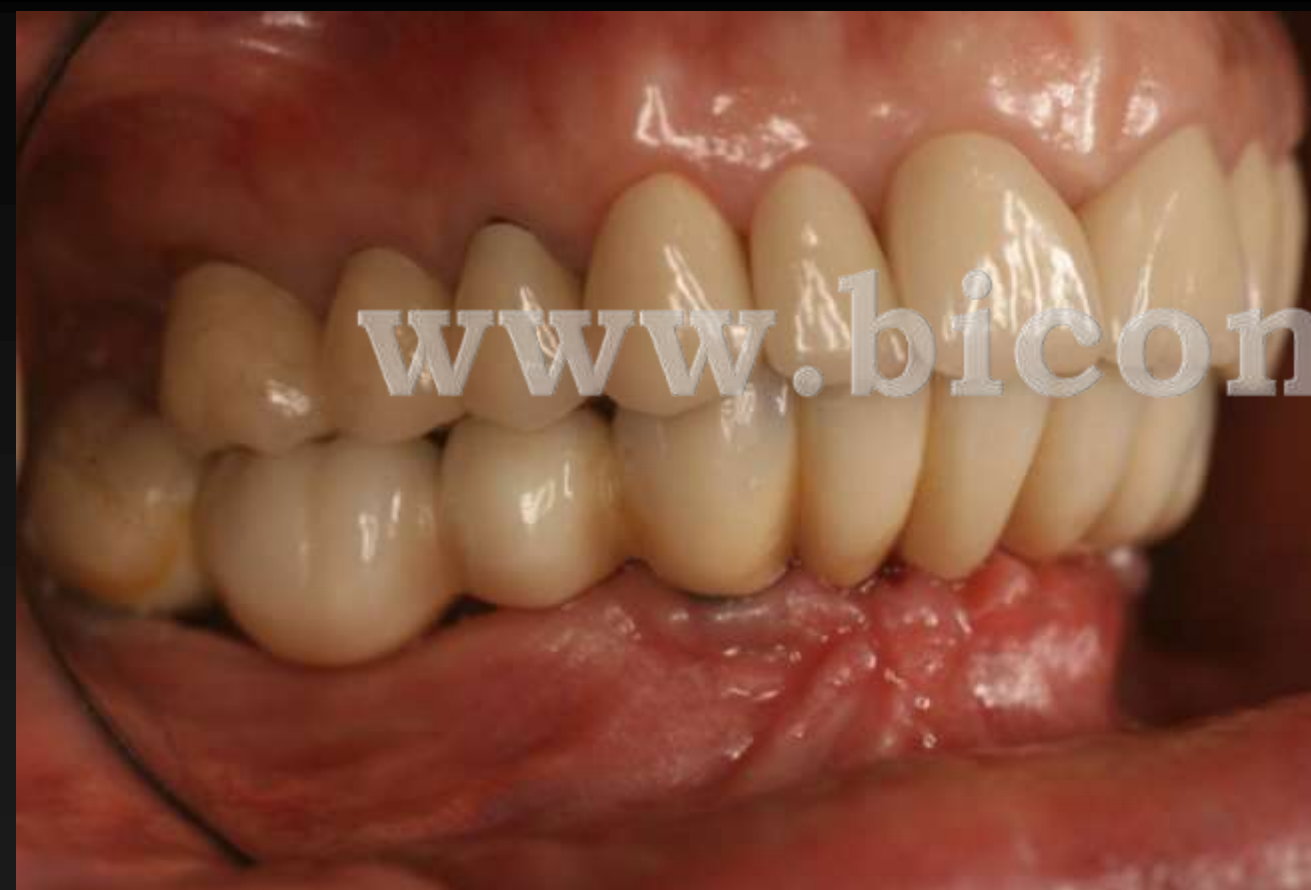Septiembre 2016



Oct 2016

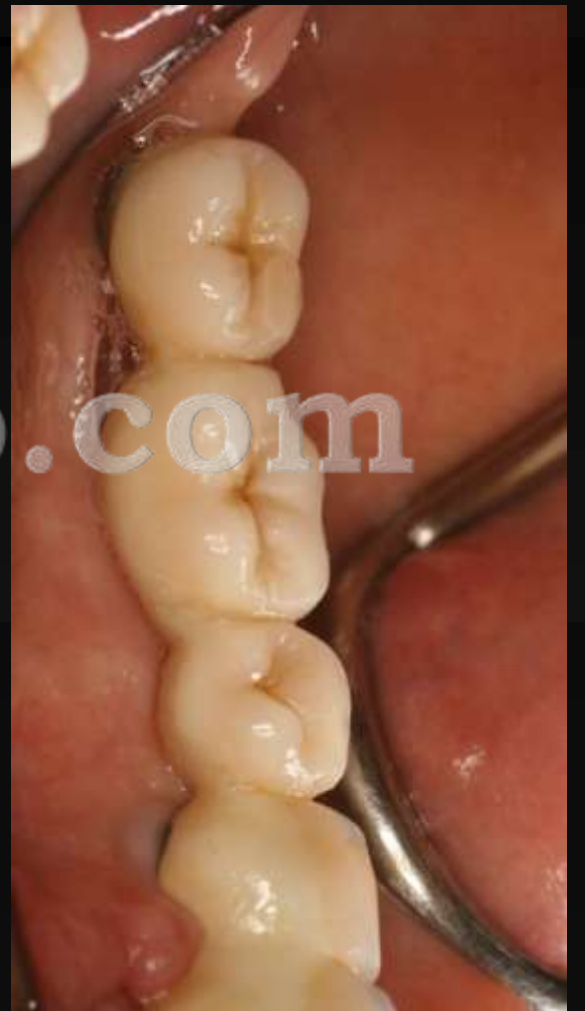
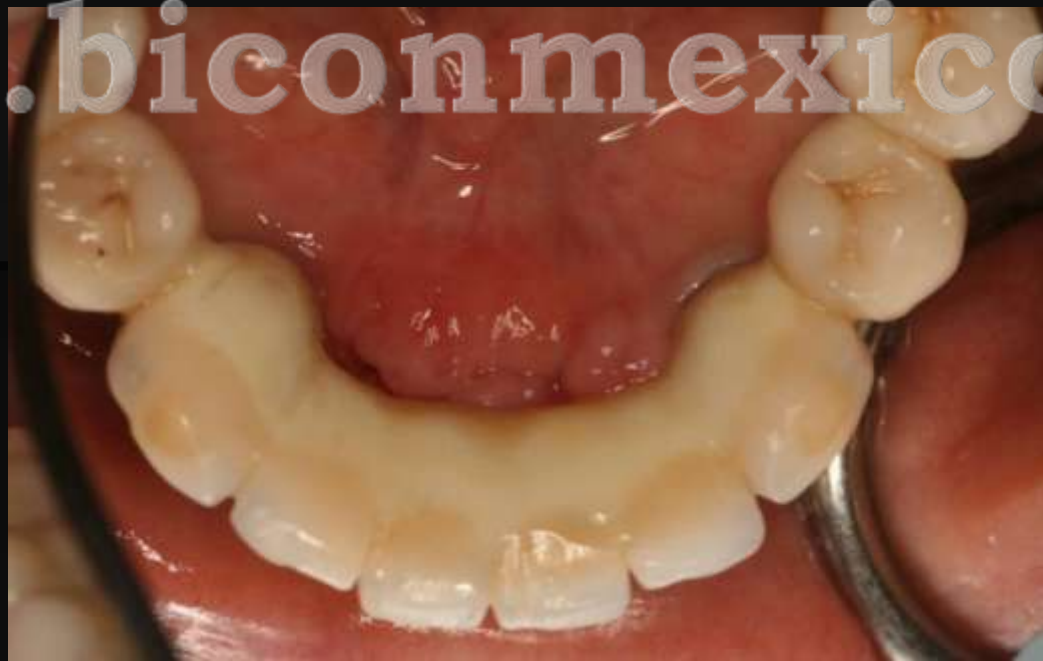
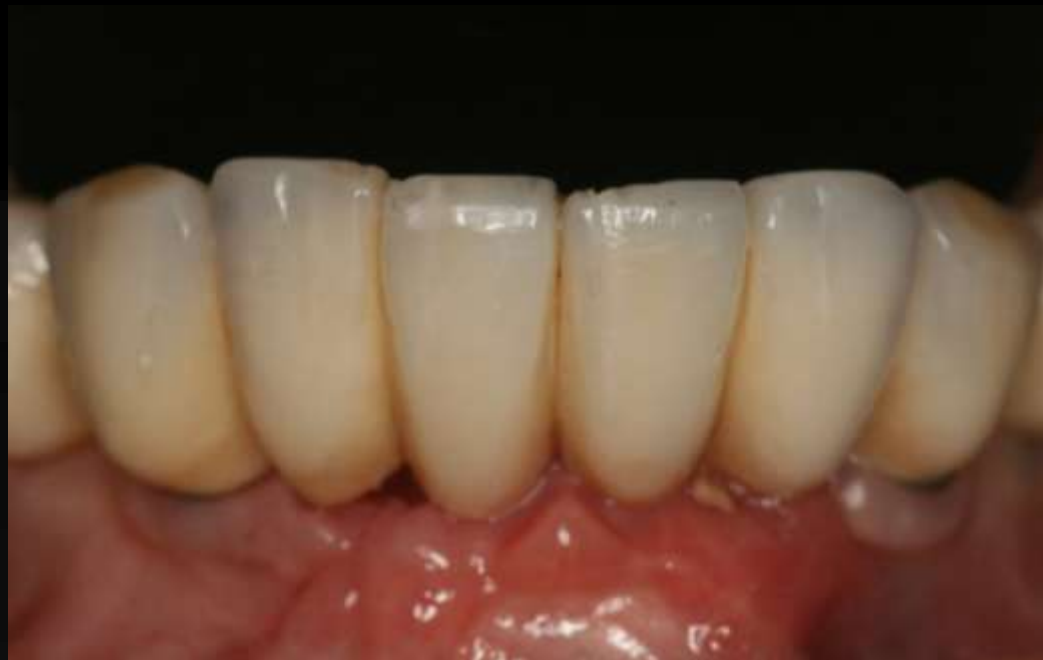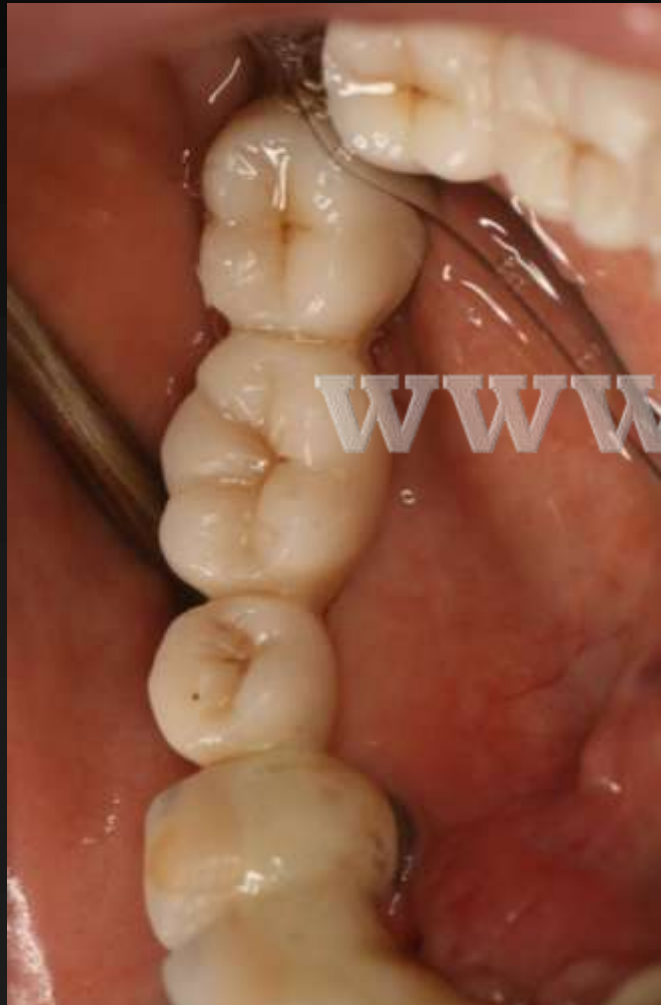All on 4 con Trinia



A close-up photograph of a patient's teeth, showing the upper and lower dental arches. The teeth are light-colored and appear to be in good health. A watermark is overlaid across the center of the image.

www.biconmexico.com



www.biconmexico.com